



This is an author produced version of a paper published in European Journal of Orthodontics. This paper has been peer-reviewed but does not include the final publisher proof-corrections or journal pagination.

Citation for the published paper:

Sonesson, Mikael; Bergstrand, Fredrik; Gizani, Sotiria; Twetman, Svante. (2017). Management of post-orthodontic white spot lesions : an updated systematic review. European Journal of Orthodontics, vol. 39, issue 2, p. null

URL: <https://doi.org/10.1093/ejo/cjw023>

Publisher: Oxford

This document has been downloaded from MUEP (<http://muep.mah.se>).

Management of post-orthodontic white spot lesions: an updated systematic review

Mikael Sonesson*, **Fredrik Bergstrand****, **Sotiria Gizani*****, **Svante Twetman******

* Lecturer, senior consultant in Orthodontics, Department of Orthodontics, Faculty of Odontology, Malmö University, Malmö, Sweden

** Specialist in Orthodontics, private orthodontic practice, Stockholm, Sweden

*** Specialist in Paediatric dentistry, Department of Paediatric Dentistry, Dental School, National and Kapodistrian University of Athens, Athens, Greece

**** Professor, Department of Odontology, Faculty of Health and Medical Sciences, University of Copenhagen, Copenhagen, Denmark

Short title: post-orthodontic WSL

Corresponding address: Dr. Mikael Sonesson

Department of Orthodontics

Faculty of Odontology, Malmö University

SE-205 06 Malmö, Sweden

E-mail: mikael.sonesson@mah.se

Key words: management, Orthodontics, post-orthodontics, white spot lesions

Management of post-orthodontic white spot lesions: an updated systematic review

Summary

Background/objectives: The management of post-orthodontic white spot lesions is based on remineralization strategies or a minimal-invasive camouflage of the lesions.

Aim: The aim of this systematic review was to identify and assess the quality of evidence for the various clinical technologies.

Search methods: Four databases were searched for relevant literature published in English between 2011 and October 31 2015 according to a pre-determined PICO. Only controlled clinical studies were considered. Abstract lists and the selected full-text papers were independently examined by two reviewers and any differences were solved in consensus. The Cochrane handbook and the AMSTAR tool were used for grading the risk of bias. The quality of evidence was rated according to GRADE.

Results: Out of 280 identified publications, 7 studies on remineralization, micro-abrasion and resin infiltration met the inclusion criteria. Two of them were assessed with low risk of bias. No pooling of results was possible due to study heterogeneity. The quality of evidence for all technologies was graded as very low.

Limitations: Only papers published in English with more than 20 adolescents or young adults were considered. Furthermore, a follow-up period of at least 8 weeks was required. The publication bias could not be assessed due to the paucity of included trials.

Conclusions/clinical implications: There is a lack of reliable scientific evidence to support remineralizing or camouflaging strategies to manage post-orthodontic white spot lesions. Further well-performed controlled clinical trials with long-term follow-up are needed to establish best clinical practice.

Introduction

White spot lesion development is a frequent side-effect to treatment with fixed orthodontic appliances (1). The prevalence is reported to vary from 2-96%, depending on method and criteria for detection as well as patient compliance with advocated preventive measures (2-4). White spot lesions can seriously jeopardize the esthetic outcome of the treatment; data indicate that such lesions have a limited ability to improve after appliance removal and white spots can sometimes be detectable even 12 years after treatment (5-7). Although primary prevention must be in focus, two major strategies on how to deal with existing lesions after debonding have been suggested; remineralizing or masking the lesions (8,9). The first is based on secondary prevention and reversing the lesions through remineralizing agents like topical fluoride, amorphous calcium phosphate or self-assembling peptides. The second strategy aims to mask and improve the esthetic appearance of the teeth through minimal-invasive measures, such as bleaching, micro-abrasion or resin infiltration. Since most published evaluations of the various technologies are made with aid of artificial lesions in vitro, the clinical benefits of the different strategies remain unclear. The aim of the present paper was therefore to examine the current evidence of effectiveness for clinical methods using remineralizing agents or minimal-invasive techniques to manage post-orthodontic white spot lesions, based on primary clinical trials and systematic reviews. This systematic review is an update of a previous publication from our research group (10) in which no firm evidence for any technology was unveiled.

Methods

The PICO was set up as follows; Population: adolescents and young adults (<30 year) with white spot lesions registered and scored within 3 months after the debonding of fixed orthodontic appliances; Intervention: any intervention, except laminate veneers, with aim to reverse the post-orthodontic

lesions or to improve their esthetic appearance; Control: no treatment, placebo or best clinical practice; Outcome: extent, hardness or appearance of white spot lesions with a follow-up period of at least eight weeks, as assessed with visual clinical scores, photographs, caries detection devices or patient/therapist satisfaction.

Search strategy and inclusion criteria – Four electronic sources were searched from 2011 throughout October 31, 2015 for systematic reviews and original studies of potential interest; PubMed, The Cochrane Library and the Citation and Trip Databases. In addition, <https://clinicaltrials.gov/> was checked for ongoing studies. The search terms were “enamel caries”, “fixed orthodontic appliances”, “fluoride”, “micro-abrasion”, resin infiltration”, “remineralization”, “tooth bleaching” and “white spot lesions” in various combinations. The full search strategy is shown in Supplement 1. The abstract list, containing 280 hits, was independently assessed by two authors and papers of potential relevance were selected. Diverging opinions were solved in consensus. For each selected abstract, the information on related papers was checked in the database. To be considered for inclusion, a full description of a controlled clinical trial (randomized or non-randomized) including more than 20 subjects was required. Furthermore, a reported endpoint obtained at least after 8 weeks and expressed as continuous or categorical data was needed. Only papers published in English were accepted. Papers describing in vitro and in situ studies with artificial white spot lesions were not taken into account. The reference lists of the accepted papers and systematic reviews were hand-searched for additional literature. A flow-chart of the inclusion of papers is shown in Figure 1.

Data extraction - Key data from the accepted studies were extracted independently by two authors and compiled in tables.

Quality assessment - The quality of the selected publications was assessed according to predetermined criteria for methodology and performance by two authors. The criteria of Cochrane handbook for

interventions (11) was used and the risk of bias for each original paper was graded as “low”, “moderate” or “high”. Systematic reviews were assessed with the AMSTAR tool as described by Mejàre et al. (12). The quality of evidence was rated with the GRADE tool (13) in four categories; strong, moderate, low and very low.

Data synthesis - Due to the low number and diversity of the included studies, a narrative descriptive synthesis was carried out. Only studies with low or moderate risk of bias were used for grading the quality of evidence.

Results

Seven primary publications (14-20), describing eight clinical trials, were included. Five studies were on remineralization agents (14-16, 19, 20), one on microabrasion (15) and two trials were on resin infiltration (17, 18) as listed in Table 1. One study (15) evaluated the management of WSL both by remineralization agents and microabrasion, thus 8 clinical trials were included. One trial was from Turkey, one from China, two from USA, two from India and one from Germany. The assessed quality is summarized in Table 2. Two of the papers were assessed as being of low risk of bias (16, 18) while the rest appeared with high risk of bias. In addition, two systematic reviews relevant for the topic were identified and both were considered being of moderate to low risk of bias (21, 22). The excluded studies (23-42) with the main reason for exclusion are shown in Table 3.

Remineralizing agents

A systematic review based on seven included studies displayed a lack of reliable evidence to support the effectiveness of remineralizing agents (fluoride and casein phosphopeptide-amorphous calcium

phosphate; CPP-ACP) for the management of post-orthodontic white spot lesions (21). This was recently confirmed in a systematic review by Raphael and Blinkhorn (22). They found a tendency towards a benefit for the use of CPP-ACP, with and without fluoride, but the quality of evidence was limited. We identified two primary studies not included in the systematic review of Chen et al. (21) but both were assessed with high risk of bias (14, 15). One study with low risk of bias compared products with various concentrations of fluoride (varnish, mousse, adult toothpaste) but no differences in improving the appearance of white spot lesions was unveiled (16). The quality of evidence was rated as very low ($\oplus\text{OOO}$) and the possible beneficial effect of re-mineralizing agents versus no treatment (natural remineralization) remains a knowledge gap.

Bleaching

No recent studies concerning bleaching of post-orthodontic white spot lesions fulfilled the inclusion criteria.

Micro-abrasion

One study compared the effects of micro-abrasion (hydrochloric acid and pumice powder) with normal tooth brushing and found that the intervention performed in a superior way over a 6 month period (15). The study displayed however a high risk of bias and the quality of evidence was graded as very low ($\oplus\text{OOO}$).

Resin infiltration

Two papers based on two split-mouth studies with resin infiltration and describing follow-up periods of 8 weeks (17) and 6 months (18) were included. In one study, the lesions were pre-treated with a fine grit polishing disc before the resin infiltration (17). The findings of both papers revealed an immediate improved esthetical appearance of the WSL's compared with untreated lesions. As only one small study with short follow-up was assessed with low risk of bias (18), the evidence for resin infiltration was graded as very low (⊕000).

Discussion

White spot lesion development is a common side-effect to orthodontic treatment with fixed appliances and a toolbox for the management after debonding is available for the informed clinician. This is the first review investigating several approaches to post-management of WSL. It is important to stress that all suggested strategies, including “no treatment”, seem to result in lesion regression or a visual masking of the lesions (15, 16, 18). This systematic review, including several clinical methods remineralizing or masking the lesions, was however unable to provide scientific support for any superior way to manage the post-orthodontic white spot lesions in an evidence-based context due to a paucity of well-performed clinical trials. The multiple narrative reviews that are available on the topic rely mainly on in vitro projects which, needless to say, cannot adequately reflect or mimic the clinical situation. There were however some study limitations. First of all, only papers published in English were accepted. Secondly, we required a minimum of 20 independent subjects, not older than 30 years of age. The rationale for this was to avoid studies with insufficient power and keep the age span as homogenous as possible. Thirdly, the 8-week follow-up was a result of a compromise; we initially selected a minimum of 6 months but realized that important information would be lost in that case. The most common reasons for exclusion were the use of artificial lesions, very short follow-up

and inadequate sample size. Thus, future studies must be powered on the number of patients rather than the number of WSL and employ a 1 year follow-up period after debonding. It was not possible to estimate the risk of publication bias through a funnel plot due to paucity of included studies.

A primary proactive preventive approach during treatment with fixed orthodontic appliances, even including early debonding, is of course best clinical practice. There is evidence of moderate quality to suggest that fluoride varnish applications around the bracket base can prevent WSL development during treatment with fixed orthodontic appliances (43) but its use, being a high fluoride product, after debonding has been questioned (44, 45). In general pediatric dentistry, there is some evidence of effectiveness to treat early enamel lesions with topical fluorides (46) but post-orthodontic lesions differ in location and extent. High concentrations of fluoride may arrest remineralization through surface hyper-mineralization and an increased risk of permanent brown organic staining, which might jeopardize the esthetic treatment result. Interestingly, the study by Huang and coworkers (16) did not demonstrate any differences in WSL improvement between a fluoride varnish application and normal home care with fluoride toothpaste when assessed by both clinicians and lay persons. As natural saliva remineralization and self-applied fluoride toothpaste is the most cost-effective alternative to deal with the problem, this strategy must be regarded as the option of choice in most cases (conditional recommendation). A watchful waiting of at least 3-6 months after debonding is advocated but the patient must be carefully re-instructed on the optimal use of the fluoride-containing toothpaste twice daily and to avoid excessive rinsing with water after brushing (47).

Micro-abrasion and resin infiltration are invasive and micro-invasive methods that obviously can camouflage more severe and long-standing cases of post-orthodontic white spot lesions in an effective way. Both methods are however technique sensitive; the former must be repeated several times, while the latter normally is a single-appointment treatment. The question whether or

not surplus etching and/or non-removed bonding material could influence the outcome was only partially addressed in the included papers but seemed not to be a problem with the infiltration approach (18). However, since the follow-up period to date is limited to 12 months (27) the long-term success rate is yet unknown. The invasive methods should therefore be used selectively on the most challenging esthetic cases or when the compliance with the advocated homecare is proven insufficient during the first months after debonding.

Conclusion

Based on current literature, there is a lack of reliable evidence to support re-mineralizing or camouflaging strategies to manage post-orthodontic white spot lesions. Since daily use of fluoride toothpaste cannot be withdrawn for ethical reasons, this must be considered as best clinical practice. Further well-conducted controlled clinical trials with extended long-term follow-up are needed to establish best clinical practice.

Acknowledgements

The authors are thankful to Ms. Hanna Wilhelmsson at the Malmö University for assisting the literature search. The authors have no conflict of interest to report. Dr. Bergstrand was a former consultant of 3M-Unitek, Stockholm, Sweden

Funding

The project was funded through the author's academic institutions.

References

1. Chapman J.A., Roberts W.E., Eckert G.J., Kula K.S., González-Cabezas C. (2010) Risk factors for incidence and severity of white spot lesions during treatment with fixed orthodontic appliances. *American Journal of Orthodontics and Dentofacial Orthopedics*, 138, 188-189.
2. Gorelick L., Geiger A.M., Gwinnett A.J. (1982) Incidence of white spot formation after bonding and banding. *American Journal of Orthodontics*, 81, 93-98.
3. Mitchell L. (1992) Decalcification during orthodontic treatment with fixed appliances – an overview. *British Journal of Orthodontics*, 19, 199-205.
4. Tufekci E., Dixon J.S., Gunsolley J.C., Lindauer S.J. (2011) Prevalence of white spot lesions during orthodontic treatment with fixed appliances. *Angle Orthodontist*, 81, 206-210.
5. Norevall L.I., Marcusson A., Persson M. (1996) A clinical evaluation of a glass ionomer cement as an orthodontic bonding adhesive compared with an acrylic resin. *European Journal of Orthodontics*, 18, 373-384.
6. Mattousch T.J., van der Veen M.H., Zentner A. (2007) Caries lesions after orthodontic treatment followed by quantitative light-induced fluorescence: a 2-year follow-up. *European Journal of Orthodontics*, 29, 294–298.
7. Shungin D., Olsson A.I., Persson M. (2010) Orthodontic treatment-related white spot lesions: a 14-year prospective quantitative follow-up, including bonding material assessment. *American Journal of Orthodontics and Dentofacial Orthopedics*, 138, 136.e1-8; discussion 136-137.
8. Knösel M., Attin R., Becker K., Attin T. (2007) External bleaching effect on the color and luminosity of inactive white-spot lesions after fixed orthodontic appliances. *Angle Orthodontist*, 77, 646-652.

9. Heymann G.C., Grauer D. (2013) A contemporary review of white spot lesions in orthodontics. *Journal of Esthetic Restorative Dentistry*, 25, 85-95.
10. Bergstrand F., Twetman S. (2011) A review on prevention and treatment of post-orthodontic white spot lesions - evidence-based methods and emerging technologies. *The Open Dentistry Journal*, 5, 158-162.
11. Higgins J.P., Altman D.G., Gøtzsche P.C., Jüni P., Moher D., Oxman A.D., Savovic J., Schulz K.F., Weeks L., Sterne J.A. (2011); Cochrane Bias Methods Group; Cochrane Statistical Methods Group. The Cochrane Collaboration's tool for assessing risk of bias in randomised trials. *British Medical Journal*, 343, d5928.
12. Mejåre I.A., Klingberg G., Mowafi F.K., Stecksén-Blicks C., Twetman S.H., Tranæus S.H. (2015) A systematic map of systematic reviews in pediatric dentistry--what do we really know? *Public Library of Science One*, 23, 10, e0117537.
13. Guyatt G., Oxman A.D., Akl E.A., Kunz R., Vist G., Brozek J., Norris S., Falck-Ytter Y., Glasziou P., DeBeer H., Jaeschke R., Rind D., Meerpohl J., Dahm P., Schünemann H.J. (2011) GRADE guidelines: 1. Introduction-GRADE evidence profiles and summary of findings tables. *Journal of Clinical Epidemiology*, 64, 383-394.
14. Agarwal A., Pandey H., Pandey L., Choudhary G. (2013) Effect of fluoridated toothpaste on white spot lesions in postorthodontic patients. *International Journal of Clinical Pediatric Dentistry*, 6, 85-88.
15. Akin M., Basciftci F.A. (2012) Can white spot lesions be treated effectively? *Angle Orthodontist*, 82, 770-775.
16. Huang G.J., Roloff-Chiang B., Mills B.E., Shalchi S., Spiekerman C., Korpak A.M., Starrett J.L., Greenlee G.M., Drangsholt R.J., Matunas J.C. (2013) Effectiveness of MI Paste Plus and

- PreviDent fluoride varnish for treatment of white spot lesions: a randomized controlled trial. *American Journal of Orthodontics and Dentofacial Orthopedics*, 143, 31-41.
17. Senestraro S.V., Crowe J.J., Wang M., Vo A., Huang G., Ferracane J., Covell D.A. Jr. (2013) Minimally invasive resin infiltration of arrested white-spot lesions: a randomized clinical trial. *The Journal of the American Dental Association*, 144, 997-1005.
18. Knösel M., Eckstein A., Helms H.J. (2013) Durability of esthetic improvement following Icon resin infiltration of multibracket-induced white spot lesions compared with no therapy over 6 months: a single-center, split-mouth, randomized clinical trial. *American Journal of Orthodontics and Dentofacial Orthopedics*, 144, 86-96.
19. Du M., Cheng N., Tai B., Jiang H., Li J., Bian Z. (2012) Randomized controlled trial on fluoride varnish application for treatment of white spot lesion after fixed orthodontic treatment. *Clinical Oral Investigations*, 16, 463-468.
20. Vashisht R., Indira R., Ramachandran S., Kumar A., Srinivasan M.R. (2013) Role of casein phosphopeptide amorphous calcium phosphate in remineralization of white spot lesions and inhibition of *Streptococcus mutans*? *Journal of Conservative Dentistry*, 16, 342-346.
21. Chen H., Liu X., Dai J., Jiang Z., Guo T., Ding Y. (2013) Effect of remineralizing agents on white spot lesions after orthodontic treatment: a systematic review. *American Journal of Orthodontics and Dentofacial Orthopedics*, 143, 376-382.
22. Raphael S., Blinkhorn A. (2015) Is there a place for Tooth Mousse in the prevention and treatment of early dental caries? *BMC Oral Health*, 15, 13.
23. Baeshen H.A., Lingström P., Birkhed D. (2011) Effect of fluoridated chewing sticks (Miswaks) on white spot lesions in postorthodontic patients. *American Journal of Orthodontics and Dentofacial Orthopedics*, 140, 291-297.

24. Ballard R.W., Hagan J.L., Phaup A.N., Sarkar N., Townsend J.A., Armbruster P.C. (2013) Evaluation of 3 commercially available materials for resolution of white spot lesions. *American Journal of Orthodontics and Dentofacial Orthopedics*, 143, S78-84.
25. Bröchner A., Christensen C., Kristensen B., Tranæus S., Karlsson L., Sonnesen L., Twetman S. (2011) Treatment of post-orthodontic white spot lesions with casein phosphopeptide-stabilised amorphous calcium phosphate. *Clinical Oral Investigations*, 15, 369-373.
26. Caglaroglu M., Gelgor I.E. (2012) Microabrasion technique for treatment of demineralization after debonding. *Journal of Clinical Orthodontics*, 46, 734-737.
27. Eckstein A., Helms H.J., Knösel M. (2015) Camouflage effects following resin infiltration of postorthodontic white-spot lesions in vivo: One-year follow-up. *Angle Orthodontist*, 85, 374-380.
28. Hammad S.M., El Banna M., El Zayet I., Mohsen M.A. (2012) Effect of resin infiltration on white spot lesions after debonding orthodontic brackets. *American Journal of Dentistry*, 25, 3-8.
29. Jahanbin A., Ameri H., Shahabi M., Ghazi A. (2015) Management of Post-orthodontic White Spot Lesions and Subsequent Enamel Discoloration with Two Microabrasion Techniques. *Journal of Dentistry (Shiraz)*, 16, (1 Suppl), 56-60.
30. Kim S., Kim E.Y., Jeong T.S., Kim J.W. (2011) The evaluation of resin infiltration for masking labial enamel white spot lesions. *International Journal of Paediatric Dentistry*, 21, 241-248.
31. Krithikadatta J., Fredrick C., Abarajithan M., Kandaswamy D. (2013) Remineralisation of occlusal white spot lesion with a combination of 10% CPP-ACP and 0.2% sodium fluoride evaluated using Diagnodent: a pilot study. *Oral Health and Preventive Dentistry*, 11, 191-196.

32. Milly H., Festy F., Watson T.F., Thompson I., Banerjee A. (2014) Enamel white spot lesions can remineralise using bio-active glass and polyacrylic acid-modified bio-active glass powders. *Journal of Dentistry*, 42, 158-166.
33. Neuhaus K.W., Graf M., Lussi A., Katsaros C. (2010) Late infiltration of post-orthodontic white spot lesions. *Journal of Orofacial Orthopedics*, 71, 442-447.
34. Paris S., Schwendicke F., Keltsch J., Dörfer C., Meyer-Lueckel H. (2013) Masking of white spot lesions by resin infiltration in vitro. *Journal of Dentistry*, 41 (Suppl. 5), 28-34.
35. Pliska B.T., Warner G.A., Tantbirojn D., Larson B.E. (2012) Treatment of white spot lesions with ACP paste and microabrasion. *Angle Orthodontist*, 82, 765-769.
36. Poosti M., Ahrari F., Moosavi H., Najjaran H. (2014) The effect of fractional CO2 laser irradiation on remineralization of enamel white spot lesions. *Lasers in Medical Science*, 29, 1349-1355.
37. Robertson M.A., Kau C.H., English J.D., Lee R.P., Powers J., Nguyen J.T. (2011) MI Paste Plus to prevent demineralization in orthodontic patients: a prospective randomized controlled trial. *American Journal of Orthodontics and Dentofacial Orthopedics*, 140, 660-668.
38. Rocha Gomes Torres C., Borges A.B., Torres L.M., Gomes I.S., de Oliveira R.S. (2011) Effect of caries infiltration technique and fluoride therapy on the colour masking of white spot lesions. *Journal of Dentistry*, 39, 202-207.
39. Yetkiner E., Wegehaupt F., Wiegand A., Attin R., Attin T. (2014) Colour improvement and stability of white spot lesions following infiltration, micro-abrasion, or fluoride treatments in vitro. *European Journal of Orthodontics*, 36, 595-602.
40. Yim H.K., Min J.H., Kwon H.K., Kim B.I. (2014) Modification of surface pretreatment of white spot lesions to improve the safety and efficacy of resin infiltration. *Korean Journal of Orthodontics*, 44, 195-202.

41. Yuan H., Li J., Chen L., Cheng L., Cannon R.D., Mei L. (2014) Esthetic comparison of white-spot lesion treatment modalities using spectrometry and fluorescence. *Angle Orthodontist*, 84, 343-349.
42. Wang J.X., Yan Y., Wang X.J. (2012) Clinical evaluation of remineralization potential of casein phosphopeptide amorphous calcium phosphate nanocomplexes for enamel decalcification in orthodontics. *Chinese Medical Journal (Engl)*, 125, 4018-4021.
43. Benson P.E., Parkin N., Dyer F., Millett D.T., Furness S., Germain P. (2013) Fluorides for the prevention of early tooth decay (demineralised white lesions) during fixed brace treatment. *Cochrane Database Systematic Reviews*, 12, 12, CD003809.
44. Øgaard B. (2008) White spot lesions during orthodontic treatment: Mechanisms and fluoride preventive aspects. *Seminars in Orthodontics*, 14, 183-193.
45. Willmot D. (2008) White spot lesions after orthodontic treatment. *Seminars in Orthodontics*, 14, 209-219.
46. Lenzi T.L., Montagner A.F., Soares F.Z., De Oliveira Rocha R. (2015) Are topical fluorides effective for treating carious lesions?: A systematic review and meta-analysis. *The Journal of the American Dental Association*, Nov5. Pii:S0002-8177(15)00701-1. Doi: 10.1016/j.adaj.2015.06.018.
47. Pitts N., Duckworth R.M., Marsh P., Mutti B., Parnell C., Zero D. (2012) Post-brushing rinsing for the control of dental caries: exploration of the available evidence to establish what advice we should give our patients. *British Dental Journal*, 212: 315-320.

Figure legend

Figure 1. Flow-chart of the included studies.

Figure 1 Flow-chart of the included studies

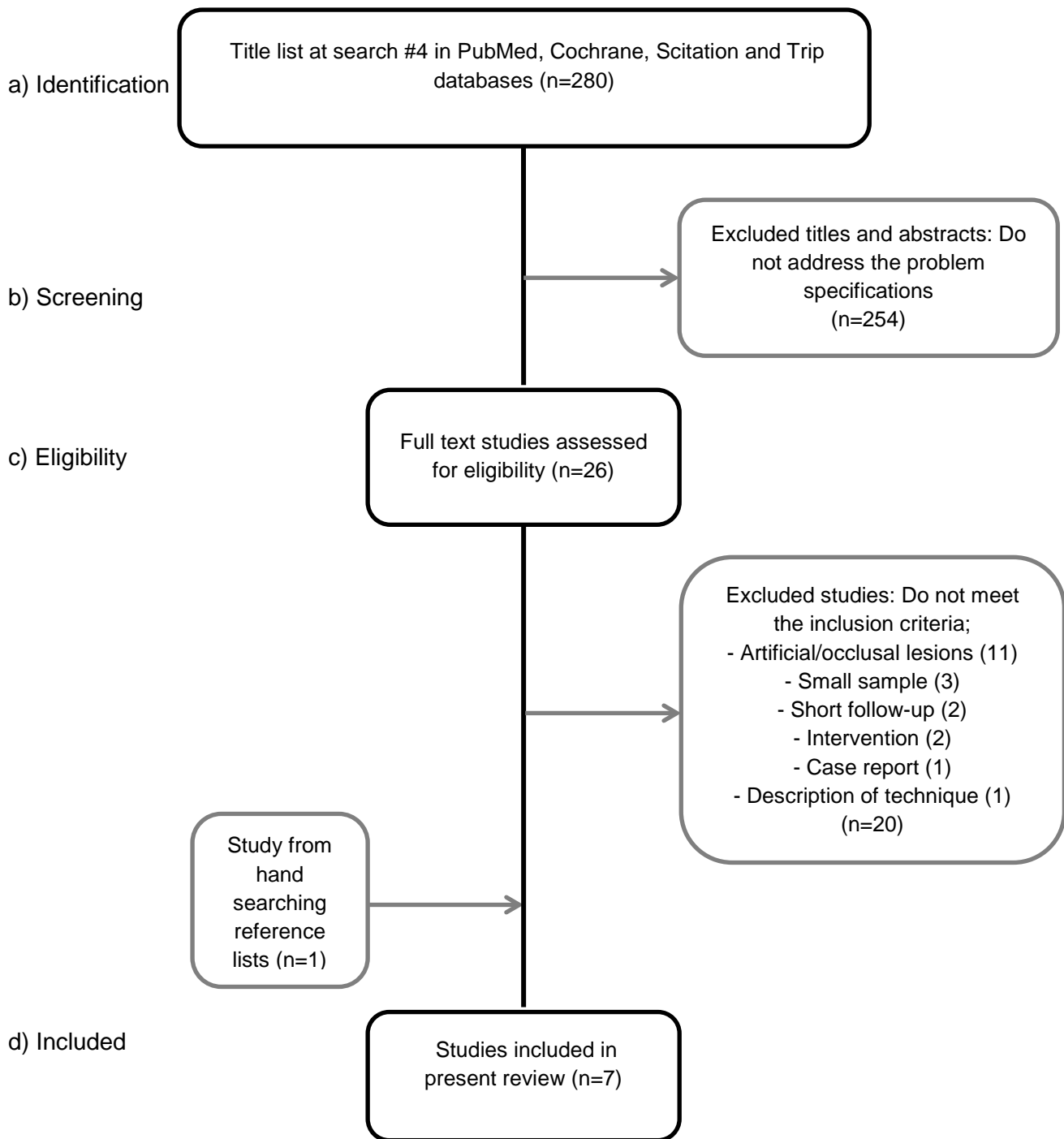


Table 1. Summary of included studies

Author, year	n, Test/ctr	FU	Intervention	Control	Outcome	Effect
<i>Remineralization agents</i>						
Agarwal, 2013 ¹⁴	31 (SM)	8 weeks	FTP	placebo	visual	S
Akin, 2012 ¹⁵	20/20	6 months	FMR	no treatment	photo	NS
	20/20	6 months	CPP-ACP	no treatment	photo	NS
Du, 2012 ¹⁹	47/49	6 months	F-varnish	saline	LF	S
Huang, 2013 ¹⁶	34/41	8 weeks	CPP-ACP ^a	home care ^b	photo	NS
	40/41	8 weeks	F-varnish	home care ^b	photo	NS
Vashisht, 2013 ²⁰	29/31	3 months	CPP-ACP	FTP	LF+visual	S
<i>Microabrasion</i>						
Akin, 2012 ¹⁵	20/20	6 months	microabr.	no treatment	photo	S
<i>Resin infiltration</i>						
Knösel, 2013 ¹⁸	21 (SM)	6 months	resin	no treatment	spectro	S
Senestraro, 2014 ¹⁷	20 (SM)	3 months	abr.+resin	no treatment	visual	S

^apaste containing 900 ppm F; ^bincluding adult fluoride toothpaste

Abbreviations: FU= follow-up; FTP=fluoride toothpaste; FMR= fluoride mouth rinse; CPP-ACP=casein phosphor peptide - amorphous calcium phosphate nano-complexes; LF=laser fluorescence; S=statistically significant difference; NS= no significant difference; SM=split-mouth

Table 2. Assessment of risk of bias for the included studies

First author, year	Type of bias					Risk level ^a
	selection	performance	detection	attrition	reporting	
<i>Remineralization agents</i>						
Agarwal, 2013 ¹⁴	yes	yes	yes	no	yes	HR
Akin, 2012 ¹⁵	yes	yes	yes	no	yes	HR
Du, 2012 ¹⁹	unclear	SB ^b	yes	no	yes	HR
Huang, 2013 ¹⁶	no	SB	no	no	no	LR
Vashisht, 2013 ²⁰	yes	yes	yes	no	yes	HR
<i>Microabrasion</i>						
Akin, 2012 ¹⁵	yes	yes	yes	no	yes	HR
<i>Resin infiltration</i>						
Knösel, 2013 ¹⁸	no	no	no	no	no	LR
Senestraro, 2014 ¹⁷	yes	yes	no	yes	yes	HR

^aHR= high risk of bias; LR=low risk of bias. ^bSB=single blind

Table 3. Excluded papers and main reason for their exclusion

First author, year	intervention	main reason for exclusion
Baeshen, 2011 ²³	fluoride	short follow-up
Ballard, 2013 ²⁴	mixed techniques	artificial lesions
Bröchner, 2011 ²⁵	CPP-ACP	short follow-up
Caglaroglu, 2012 ²⁶	abrasion	description of technique
Eckstein, 2015 ²⁷	resin infiltration	small sample
Hammad, 2012 ²⁸	resin infiltration	small sample, short follow-up
Jahanbin, 2015 ²⁹	micro-abrasion	artificial lesions
Kim, 2011 ³⁰	resin infiltration	small sample, short follow-up
Krithikadatta, 2013 ³¹	CPP-ACP	occlusal lesions
Milly, 2014 ³²	bioactive glass	artificial lesions
Neuhaus, 2010 ³³	resin infiltration	case report
Paris, 2013 ³⁴	resin infiltration	artificial lesions
Pliska, 2012 ³⁵	abrasion+ACP	artificial lesions
Poosti, 2014 ³⁶	laser	artificial lesions
Robertson, 2011 ³⁷	CPP-ACP	intervention during FOA
Torres, 2011 ³⁸	infiltration+fluoride	artificial lesions
Yetkiner, 2014 ³⁹	mixed techniques	artificial lesions
Yim, 2014 ⁴⁰	resin infiltration	artificial lesions
Yuan, 2014 ⁴¹	methodology	artificial lesions
Wang, 2012 ⁴²	CPP-ACP	intervention during FOA

Abbreviations: CPP-ACP=casein phosphor peptide - amorphous calcium phosphate nanocomplexes;
FOA=fixed orthodontic appliances